

The Safety and Efficacy of Clipless *versus* Conventional Laparoscopic Cholecystectomy – our Experience in an Indian Rural Center

Rikki SINGAL, Muzzafar ZAMAN, Amit MITTAL, Samita SINGAL

Department of Surgery, M.M. Institute of Medical Sciences and Research,
Mullana (Distt-Ambala), Haryana, India

ABSTRACT

Background: Laparoscopic cholecystectomy is one of the most common surgeries performed nowadays. There are lot of advances in closure of cystic duct and artery (clip ligation, suture ligation), but it remains an enigma regarding efficacy, safety and postoperative complications for using non-absorbable suture material or Liga clip for the operating surgeon in laparoscopic cholecystectomy.

Objectives: Our study aimed to evaluate the efficacy, safety and complications of non-absorbable sutures ligation versus clips application in laparoscopic cholecystectomy, and to compare the operative time and cost effectiveness of the two surgical approaches in laparoscopic cholecystectomy.

Methods: This prospective study was performed between August 2014 and February 2015 in M. M. Institute of Medical Science and Research, in a rural center, Mullana, India. The study included 160 patients who were diagnosed with chronic cholecystitis in a single unit. Subjects were divided into two groups and all cases were operated by a single surgeon. The cystic pedicle was tied with non-absorbable material (silk 2-0) in group A and with Titanium clips using a clip applicator in group B.

Results: The application of silk and clips for cystic duct and artery ligation in laparoscopic cholecystectomy can be safely used. The mean time for ligation of cystic duct was 2.50 (SD ± 0.25) in group A and 1.50 min (SD ± 1.85) in group B, with $P < 0.001$, which was significant. Similarly, the mean time for ligation of cystic artery was 1.50 min (SD ± 0.20) in group A and 1.36 min (SD ± 0.11) in group B, with $P > 0.001$. There were no postoperative complications, such as wound infection or bile leakage, in any of the two methods. The cost of material for silk suture (40-60 Rupees or 0.62–0.92 \$) is definitely much lower than that for Liga clips (790-1000 Rupees or 12.28–15.55 \$). For the use of clips, a clip applicator is required, but in case of silk ligation no special instrument is required and silk is also easily available.

Conclusion: In laparoscopic cholecystectomy, ligation of cystic duct and cystic artery with clips takes less time than by silk suture. We conclude that both ligation techniques can be safely and effectively used. Training for junior surgeons is necessary to avoid potential complications.

Keywords: cholecystectomy, surgical training, intracorporeal ligation, bile leakage, bleeding.

Address for correspondence:

Samita Singal,

c/o Dr Kundan Lal Hospital,

Ahmedgarh, Distt. Sangrur, Punjab, Pin Code 148021, India

Mobile: 09996184795, Fax: 01731304550

Email: simisingal@yahoo.co.in

Article received on the 19th of June 2017 and accepted for publication on the 18th of December 2017.

INTRODUCTION

With the introduction of laparoscopic surgery, management of gallstones became easy and it has been considered the gold standard procedure as compared to open cholecystectomy. Cholelithiasis and its consequences are the main cause of surgical entry into the peritoneal cavity. So widespread is this entity that it will not be out of place to state that cholecystectomy is routinely done (1). Minilaparoscopic cholecystectomy (MLC) could lead to small benefits without increased risk for postoperative complications, which makes it an excellent candidate for routine elective cholecystectomy. These approaches may be imposed sometime as standard treatment by the use of robotization (2).

Laparoscopic surgery has become the method of choice for treatment of symptomatic and uncomplicated gallbladder stones, appendectomies and hernia repair (3). In laparoscopic cholecystectomy (LC), cystic duct and cystic artery are normally secured with Titanium clips. Intracorporeal ligation is usually superior to extracorporeal knotting. Most studies describe separate and multiple ligations of cystic duct and cystic artery, which are viewed as technically demanding and time consuming. Similarly, the harmonic scalpel and ligasure are prohibitory expensive for resource limitations. After several modifications, the success of intracorporeal "single ligation of cystic duct and cystic artery" with silk 2/0 was observed. The time taken for tying varied from two to seven minutes, and no bile leak or other complication were noted (4).

We studied the efficacy and safety of silk as compared to clip application for cystic duct and artery ligation separately. We observed that both techniques were safe and less time consuming, but silk ligation has been proven to be more secure than clip application. Even silk can be easy to handle and freely accessible anywhere, which is particularly important when working in rural centres. But for clipping, clip applicator and Liga clips are required. Also, special care is needed to handle and clean the instrument. Both techniques are safe and we have not encountered any complications in our study. ■

METHODS

The study was carried out between August 2014 and February 2015, in the Department of General Surgery, M. M. Institute of Medical Science and Research, Mullana, India, in a single unit. Ethical clearance was taken from the institute board members. In total, 160 patients aged 18-80 years were selected and divided into two groups of 80 subjects each; all of them underwent LC. It was found that the disease was most common in the third decade of life for 55 (68.75%) patients in both groups; 34 (42.5%) patients aged 31-40 years and 25 (31.25%) aged 41-50 presented in the fourth decade of life (Table 1). It was found that the disease was predominant in women. In group A (silk ligation) there were 63 females and 17 males, and in group B (clip ligation) 57 females and 23 males (Table 2).

Age (years)	Group A	Group B	Total	Percentage
21-30	16	18	34	42.5%
31-40	34	21	55	68.75%
41-50	14	11	25	31.25%
51-60	12	21	33	41.25%
61-70	4	9	13	20%

TABLE 1. Age distribution in both groups

Sex	Group A		Group B	
	No. of patients (n=80)	Percentage	No. of patients (n=80)	Percentage
Female	62	77.5%	66	82.5%
Male	18	22.5%	14	17.5%
Total	80	100%	80	100%

TABLE 2. Sex distribution in both groups

Group A consisted of 70 patients who underwent LC using cystic duct and artery ligation with silk 2-0. Group B also consisted of 70 patients in whom cystic duct and cystic artery were ligated with Liga clips – two large size clips were applied on the cystic duct and two medium size Liga clips on the cystic artery (Figure 1). All the 160 patients (100%) had a history of pain prior to their admission in hospital. Presenting complaints were nau-



FIGURE 1. Material used for ligating and clipping the cystic duct and artery

sea, nausea associated with vomiting in 21 (35%) cases, along with occasional episodes of pain as the second most common symptom. Sixteen (26.67%) patients had dyspepsia with pain on and off. None of the patients presented with fever or jaundice. The cases were randomly allocated by a sealed envelope method into the study group A (70 cases) and the control group B (70 cases), and 20 patients were excluded from the study. All cases included in this study were diagnosed as having chronic cholecystitis with cholelithiasis. Excluded patients presented acute cholecystitis, empyema gallbladder, disarranged coagulation profile, pregnancy, etc.

Procedure

All patients received preoperative medication: antibiotic (1 mg), metrogyl (100 mL) and anxit tablet (0.25 mg). A 10 mm infraumbilical port was made for camera, followed by three 5 mm ports. After completion of Callot's triangle, a proper exposure of the cystic artery and cystic duct was made. In group A, non-absorbable suture (silk 2-0) was pushed in the abdominal cavity in appropriate size through the epigastric port and kept in the callot's triangle. With the help of laparoscopic instruments (Maryland and grasper), the cystic duct or cystic artery was tied or vice versa separately and the time was recorded. The thread was encircled around the cystic duct proximally and distally as single tie respectively, and then cut. The remaining part of the thread was used for ligation of the cystic artery proximally and distally

as single tie. Out silk tie was secured enough with single tie by observing the colour of the cystic duct which turned whitish, meaning the note was tightened. By making a single tie, we saved time as compared to clip application in group B, where three clips were applied over the cystic duct and three over the artery. In group B, Liga clips were applied on the cystic duct and artery. Three large sized clips were applied over the cystic duct (two proximal and one distally) and three medium Liga clips over the cystic artery separately with the help of the clip applicator. The procedure was completed as LC. Drain was placed in the sub hepatic area in all patients and hence, the procedure was completed as four ports LC.

Patients were evaluated daily until discharge. Their vitals and volume of drain were noted daily. Drain was removed when the volume decreased to <20 mL/24 hours. All patients were discharged from surgery as early as possible. Postoperatively, all patients were observed for any. □

RESULTS

A total number of 140 patients were randomly selected and divided into two groups, A and B. Those in whom the cystic pedicle was ligated with silk suture were assigned to group A (70 cases) and the subjects in whom Liga clips were used to group B (70 cases) (Figures 2 and 3, respectively). The mean time for completion of the entire procedure was 26.47 min (SD ± 6.05) for group A and 23.63 min (SD ± 6.42) for group B (P value 0.135). In group A, the maximum time taken for ligation of the cystic duct was 2-3 minutes in 56 patients and 1-2 min for ligation of cystic artery in 52 patients, whereas in group B it was 1-2 minutes for both cystic duct clipping (57 patients) and cystic artery (68 patients). We observed that the colour of the cystic duct changed to whitish with appreciate ligation (by silk) of the cystic duct proximally and distally. The mean time for ligation of the cystic duct was 2.50 minutes (SD ± 0.25) in group A and 1.50 minutes (SD ± 1.85) in group B, with P value <0.001, which was significant. Similarly, the mean time for ligation of the cystic artery was 1.50 minutes (SD ± 0.20) in group A, and 1.40 minutes (SD ± 0.11) in group B, with a P value >0.001, which was non-significant (Table 3). The time taken for cystic duct ligation

by silk was longer than for cystic artery ligation. But time consumption was similar for ligation of the cystic artery by silk or clip. The mean volume of drain output in group A, on day 1, day 2 and day 3 was 25.50 minutes (SD \pm 26.76), 10.40 minutes (SD \pm 16.64) and 2.50 minutes (SD \pm 5.00), respectively.

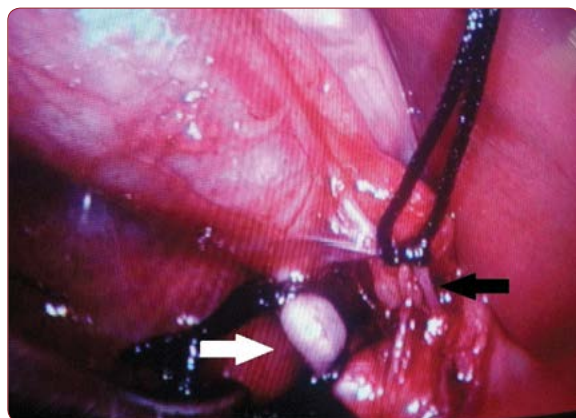


FIGURE 2. Operative picture showing ligating the cystic duct (marked with white arrow) and cystic artery (marked with black arrow)

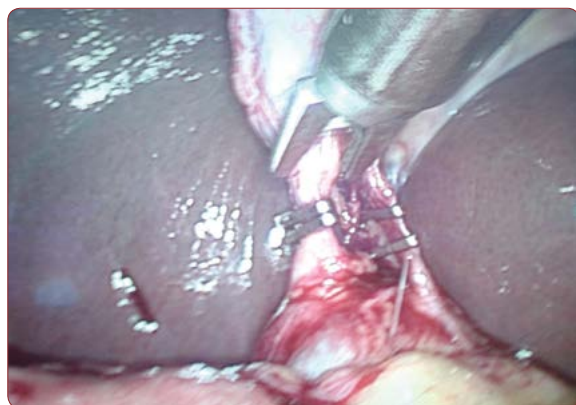

FIGURE 3. Gross operative section revealed clipping the cystic duct and artery with the clip applicator (marked with arrow)

No major differences were seen between groups in terms of inpatient stay, postoperative complications and safety of the procedure. Hospital stay in both groups was similar (two to three days). Ryle's tube was removed in the evening on the same day of surgery. Next day, patients were allowed oral sips of water and by the evening full diet. From the moment patients started taking orally, they were discharged after 48 hours. In four cases, the hospital stay was three to four days. All patients were observed for any fever, wound infection, bleeding, intra-abdominal col-

Time in minutes	Group A (suture ligation)		Group B (clips ligation)		P value
	Cystic duct	Cystic artery	Cystic duct	Cystic artery	
1-2	04	52	57	68	<0.001
2-3	56	14	13	02	
3-4	10	04	00	00	

TABLE 3. Time for ligation of cystic duct and cystic artery

Complications	Group A	Group B
Bile leakage	None	None
Migration of clips	None	None
Slipping of knot	None	None
Wound infection	None	None
Postoperative pyrexia	None	None

TABLE 4. Postoperative complications in both groups

lection and prolonged hospital stay. They were followed for two months to see if any complications occur. In both groups, no complications were noted, except for the little prolonged timing in group A as compared to group B (Table 4). The price of suture material used during the study was only 40-60 Rupees, whereas the cost of titanium clips used for clipping was far more expensive (790-1000 Rupees). This suggests that the use of suture for ligation is cost-effective and economical for ligation. □

DISCUSSIONS

Laparoscopy is widely practiced and it offers realistic benefits over conventional surgery (5). It was first performed by Carl Langenbuch in 1882, and in 1983 Kurt Semm used an automatic insufflation device for assessing intra-abdominal pressures (6). Laparoscopic cholecystectomy is being increasingly performed as a day surgery procedure. Evidence showed that there was no significant difference in morbidity between day surgery procedure and overnight stay, and both approaches had similar prolonged hospitalization and readmission rate. In addition, there was no significant difference in the visual analogue scale score, postoperative nausea and vomiting scale, time to return to activity and work between the two groups. Laparoscopic cholecystectomy can

be performed safely in selected patients as a day surgery procedure (7). The cystic duct and artery are normally closed with titanium clips. They declared no bile leakage or other problems with intracorporeal ligation of the cystic duct/artery by silk 2/0. The time required for tie varied from two to seven minutes. It was reported that cystic duct and artery were normally secured with titanium clips. Intracorporeal ligation is normally superior to extra corporeal knotting. Single ligation of artery and duct is safe and economical (4).

A study reported on the safety of instruments used for LC in 60 patients. The duration of surgery was 33.1 ± 10 minutes when clips were used (Group A), 31.5 ± 11.1 minutes when Harmonic scalpel was used (Group B), and 36.5 ± 9.9 when bipolar vessel sealer was used (Group C). The difference between Group B and Group C was statistically significant ($P < 0.04$). For all of these three groups, the total cost was 900 \$, 2900 \$, and 1800 \$, respectively. The authors observed that different energy source equipments may be safe for patients to use with a cautious dissection and sealing of the cystic duct in LC (8). Gurusamy KS (9) found that it was necessary to close the cystic duct completely during LC to avoid leak from stump. There was a statistically significant longer operating time (mean difference 12.00 minutes) in the ligature group than in the non-absorbable clips group (9).

Another study performed the 'C' technique for closure of the cystic duct in 1000 consecutive patients subjected to LC as intracorporeal knotting. Neither bile leakage nor any other procedure-related complication was seen. The mean time taken for cystic duct ligation was 3.5 minutes. The method of total intracorporeal cystic duct and artery ligation in LC is simple, technically easy, secure, and economical (10). In our study, the time for ligation of the cystic duct was 2.50 ± 0.25 minutes, which was comparable with that reported by the previously mentioned study. But the mean time taken for cystic ligation by silk was 1.50 minutes, as repeated insertion of silk was not required. Because for cystic duct ligation we needed a longer thread during insertion than for group B, re-insertion of the applicator was required every time. So, the time for ligation of the cystic artery was shorter than for ligation of the cystic duct. The time required for cystic artery ligation with clip or silk was almost the same. We noted no postoperative bile leakage. Another

study reported that the time from skin incision to closure of wound was 46.6 minutes in the clip group and 70.7 minutes in the ligature group. The authors observed that the operative time was longer when using intracorporeal knotting as compared with clip application, but the difference was not statistically significant ($P = 0.493$) (11). We also share their observations, as surgeons are not used to intracorporeal knotting, but we observed that ligation of the cystic duct or artery is more secure when silk was used as compared with clips. If you start using intracorporeal knotting routinely, the procedure becomes less time consuming with the increasing number of cases done.

A study found that the average operative time was 61.29 minutes (25-160). The authors found 12 patients with minor complications but did not prolong the hospital stay. There were five (4.1%) patients with intraoperative bleeding, but all cases were controlled. Fever on the second postoperative day occurred in four (3.3%) patients without obvious causes. Intraabdominal collection (bile leakage) occurred in one patient (0.8%) who was readmitted and managed conservatively. This patient was fully recovered by conservative treatment (12). Ghavidel A et al (13) found that post-cholecystectomy clip migration was rare, but could lead to complications such as clip-related biliary stones. Most of such incidents have been reported as case reports in the literature. It can occur at any time but mostly after a median period of two years post-cholecystectomy (13). In our group, there was no such complication neither any leakage from the bile duct was observed in the postoperative period.

Other authors observed more benefits of the simple ligation of cystic duct. It is easy and practical as intracorporeal knotting needs special expertisation. This is a simple technique that could be performed without any difficulty. Beyond doubt, simple ties are always available and very economic (14). Another study revealed that intracorporeal knotting and endoloop closure were safe, successful and feasible methods for appendectomy. The authors observed that silk was a better alternative option to ligate the base of the appendix as compared to harmonic-like device. Hence, in rural locations, or in settings where instruments are not affordable to the surgeon, or in financially compromised patients, silk can be used without any complication (15). Mehmedovic Z

et al (16) declared that LC was associated with a higher risk of intraoperative lesions and primarily lesions of biliary ducts. In a small percentage of cases, biliary fistulas occur, most commonly after leakage from cystic duct stump or accessory bile ducts (16). Our study observed that with the tight secure of silk to the cystic duct, the colour of the duct changed to white. We have not come across any kind of injury in any group.

Cystic duct leakage with metal clips persists after laparoscopic cholecystectomy (17). Use of locking clips on leaks from the cystic duct stump after LC is an alternative to metal clips (17). A study noted the migration of two clips into the common bile duct (CBD) along with retained stones as rare complications of LC, and highlighted that it should be kept in mind as differential diagnosis of recurrent cholangitis in post-cholecystectomy cases (18). An author described an intraductal migration of surgical clips into the CBD after 10 years of LC, which was unusual and could result in gallstone formation clip cholelithiasis (19). Photi ES *et al* (20) have done the ligation of the cystic duct with surgical clips, and reported a case of cholangitis secondary to clip migration into the CBD. Another case was reported as postoperative Mirizzi syndrome caused by the migration of four polymer laparoscopic clips, which could confuse the diagnostic and therapeutic field for treatment (21). A study reported a case of bile leak caused by an injury to the ducts of Luschka after LC; the leak was treated with ES using 5-F NBT, and the resolution of the leak was confirmed without repeated endoscopy (22). In our study, no such complication was encountered (Table 5). Another study observed bile leakage in two (0.82%) patients postoperatively. In one case, it was found that the clip had slipped from the cystic duct (23). We applied the clips with keeping the distance from the cystic and CBD junction, which may be the reason of non-migration of clips into the CBD. Though it was our observation, large series of studies required to mention it.

We believe that, if LC is performed under safety guidance and meticulously, then complications may be decreased. One more observation in our study was that silk ligation was a safer option than clip application to avoid the CBD stricture formation or migration. During

Authors	Migration of clips	Bile duct leakage	Percentage
Shah JN <i>et al</i> (2010) ⁴	0	0	
Golash V (2008) ¹⁰			0
Ghavidel A <i>et al</i> (2015) ¹³	1		
Mehmedovic Z(2016) ¹⁶		1	
Matsui Y <i>et al</i> (2015) ¹⁷	0	0	
Rawal KK <i>et al</i> (2017) ¹⁸	2		
Cookson NE <i>et al</i> (2015) ¹⁹	1		
Photi ES <i>et al</i> (2014) ²⁰	1		
Nagorni EA (2016) ²¹	4		
Ko SY (2017) ²²		1	
Farooq U ²³		2	1
Our study	0	0	0

TABLE 5. Postoperative complications by authors' reports

the study it was noted that repeated insertion of the clip applicator was required for clipping but in case of silk ligation, only one time thread was inserted and kept near the callots triangle or dissected area. The cystic duct or artery vice versa could be ligated separately with a piece of thread, though there were no major differences in the form of timing.

In our study, the cost of silk suture was much cheaper than that of titanium clips used for the cystic duct and artery. For the suture material used during the study, the price was only 40–60 Rupees (0.62–0.92 \$), whereas for the titanium clips used for clipping it was far higher, reaching 790–1000 Rupees (12.28–15.55 \$). This suggests that the use of suture for ligation is a very cost-effective and economic option for ligation. In the present study, surgery was performed by a single surgeon to avoid complications, as operating time would vary among surgeons. With the use of silk, epigastric port size can be reduced from 10 mm to 5 mm. Therefore, the advantages of the present study include: 1) suture ligation needs skills and experience, which can be improved by training; 2) when the colour of the cystic duct becomes white, it means that silk tied to the cystic duct is secure enough; 3) suture is readily available everywhere, but the availability of clips can be sometime questioned even in terms of appropriate size; 4) the cost of clips is much higher than that of silk; 5) silk is easy to apply in dilated or short cystic duct. □

CONCLUSION

The use of silk or clips can produce effective and safe ligation of the cystic duct or artery during laparoscopic cholecystectomy. When clip applicator is not available, suture can be alternatively used. The laparoscopic surgeon should be well versed with both techniques.

Total timing and complications also depend on surgeons' or residents' experience and skills, and can be lowered with proper training and guidance. □

Conflicts of interest: none declared.

Financial support: none declared.

REFERENCES

1. Singal R, Singal RP, Sandhu K, Singh B, Bhatia G, Khatri A, Sharma BP. Evaluation and comparison of postoperative levels of serum bilirubin, serum transaminases and alkaline phosphatase in laparoscopic cholecystectomy versus open cholecystectomy. *J Gastrointest Oncol* 2015;6:479-486.
2. Gaillard M, Tranchart H, Lainas P, Dagher I. New minimally invasive approaches for cholecystectomy: Review of literature. *World J Gastrointest Surg* 2015;7:243-248.
3. Zaman M, Singal S, Singal R, Shah A, Sandhu KS, Singh B, Khera A, Bassi S. Comparison of Open and Closed Entry Techniques for Creation of Pneumoperitoneum in Laparoscopic Surgery in Terms of Time Consumption, Entry-related Complications and Failure of Technique. *World J of Laparoscopic Surg* 2015;8:69-71.
4. Shah JN, Maharjan SB. Clipless laparoscopic cholecystectomy—a prospective observational study. *Nepal Med Coll J* 2010;12:69-71.
5. Singal R, Zaman M, Mittal A, Singal S, Sandhu K, Mittal A. No need of fascia closure to reduce trocar site hernia rate in laparoscopic surgery: a prospective study of 200 non-obese patients. *Gastroenterology Res* 2016;9:70-73.
6. Gupta R, Singal R, Sharda VK, Singh B, Ahluwalia JS, Bhatia G, Arora G. Two port laparoscopic assisted appendectomy versus three port laparoscopic appendectomy: A prospective study of 50 cases. *Trop J Med Res* 2015;18:14-19.
7. Tang H, Dong A and Yan L. Day surgery versus overnight stay laparoscopic cholecystectomy: A systematic review and meta-analysis. *Dig Liver Dis* 2015;47:556-561.
8. Bulus H, Basar O, Tas A, Yavuz A, Akkoca M, Coskun A, et al. Evaluation of three instruments for laparoscopic cholecystectomy: harmonic scalpel, bipolar vessel sealer, and conventional technique. *Minerva Chir* 2013;68:537-542.
9. Gurusamy KS, Bong JJ, Fusai G, Davidson BR. Methods of cystic duct occlusion during laparoscopic cholecystectomy. *Cochrane Database Syst Rev* 2010;6:CD006807.
10. Golash V. An experience with 1000 consecutive cystic duct ligation in laparoscopic cholecystectomy. *Surg Laparosc Endosc Percutan Tech* 2008;18:155-156.
11. Deepak Sharma, Brijesh Sharma, Mahesh Solanki. Laparoscopic Cholecystectomy: Cystic Duct Occlusion with Titanium Clip or Ligature. *International Journal of Science and Research* 2016;11:1909-1912.
12. Narongsak Jongsiri MD. How to Secure Cystic Duct Ligation for Laparoscopic Cholecystectomy – Back to Simple Basic. *The Thai Journal of Surgery* 2009;30:29-33.
13. Ghavidel A. Migration of clips after laparoscopic cholecystectomy; a case report and literature review. *Middle East J Dig Dis* 2015;71:45-49.
14. El-Geidie AA. Single-incision laparoscopic cholecystectomy (SILC) using harmonic scalpel. *J Surg Res* 2012;176:50-54.
15. Singal R, Zaman M, Mittal A, Singal S. Evaluation of intracorporeal knotting and endoloop closure in laparoscopic appendectomy. *Hellenic Journal of Surgery* 2016;4:225-228.
16. Mehmedovic Z, Mehmedovic M, Hasanovic J. A rare case of biliary leakage after laparoscopic cholecystectomy-diagnostic evaluation and nonsurgical treatment: a case report. *Acta Inform Med* 2015;2:116-119.
17. Matsui Y, Yamaki S, Yamamoto T, Isizaki M, Matsui K, Yanagimoto H, et al. Absence of cystic duct leakage using locking clips in 1017 cases of laparoscopic cholecystectomy. *Am Surg* 2012;11:1228-1231.
18. Rawal KK. Migration of Surgical Clips into the Common Bile Duct after Laparoscopic Cholecystectomy. *Case Rep Gastroenterol* 2017;3:787-792.
19. Cookson NE, Mimezami R, Ziprin P. Acute Cholangitis following Intraductal Migration of Surgical Clips 10 Years after Laparoscopic Cholecystectomy. *Case Rep Gastrointest Med* 2015;2015:504295.
20. Photi ES, Partridge G, Rhodes M, Lewis MPN. Surgical clip migration following laparoscopic cholecystectomy as a cause of cholangitis. *Journal of Surgical Case Reports* 2014; 2014(4):rju026. doi:10.1093/jscr/rju026.
21. Nagorni EA, Kouklakis G, Tsaroucha A, Foutziti S, Courcousakis N, Romanidis K, et al. Post-laparoscopic cholecystectomy Mirizzi syndrome induced by polymeric surgical clips: a case report and review of the literature. *J Med Case Rep* 2016;10:135.
22. Ko SY, Lee JR, Wang JH. Endoscopic Nasobiliary Drainage for Bile Leak Caused by Injury to the Ducts of Luschka. *Korean J Gastroenterol* 2017;2:147-150.
23. Farooq U, Rashid T, Naheed A, Barkat N, Iqbal M, Sultana Q. Complications of laparoscopic cholecystectomy: an experience of 247 cases. *J Ayub Med Coll Abbottabad* 2015;2:407-410.