

## Angiographic quantification of aortic regurgitation following myval octacor implantation; independent core lab adjudication

Ahmed Elkoumy<sup>a,b</sup>, John Jose<sup>c</sup>, Sengottuvelu Gunasekaran<sup>d</sup>, Asish Kumar<sup>e</sup>, B.C. Srinivas<sup>f</sup>, C.N. Manjunath<sup>g</sup>, K.S. Ravindranath<sup>h</sup>, Maulik Parekh<sup>i</sup>, Praveen Chandra<sup>j</sup>, Rajneesh Kapoor<sup>h</sup>, Mahmoud Abdelshafy<sup>a</sup>, Ashok Seth<sup>i</sup>, Praveer Agrawal<sup>i</sup>, Atul Mathur<sup>i</sup>, Ravindra Singh Rao<sup>j</sup>, Hesham Elzomor<sup>a</sup>, K.S. Sadanada<sup>k</sup>, Vijay Kumar<sup>l</sup>, Shahram Arsang-Jang<sup>a,m</sup>, Sanjay Mehrotra<sup>n</sup>, Bagirath Raghuraman<sup>n</sup>, Uday Khanolkar<sup>n</sup>, Rajendra Kumar Premchand<sup>o</sup>, Manik Chopra<sup>p</sup>, Prem Krishna<sup>q</sup>, Haresh Mehta<sup>r</sup>, Rahul Gupta<sup>s</sup>, Viveka Kumar<sup>t</sup>, Nagendra Boopathy Senguttuvan<sup>u</sup>, Andreas Baumbach<sup>v</sup>, Patrick W. Serruys<sup>a,m</sup>, Osama Soliman<sup>a,m,\*</sup>

<sup>a</sup> Discipline of Cardiology, Saolta Group, Galway University Hospital, Health Service Executive and CORIB Core Lab, University of Galway, H91 V4AY Galway, Ireland

<sup>b</sup> Islamic Center of Cardiology, Al-Azhar University, Nasr City, Cairo 11651, Egypt

<sup>c</sup> Department of Cardiology, Christian Medical College & Hospital, Vellore 632004, India

<sup>d</sup> Department of Cardiology, Apollo Main Hospital, Greaves Road, Chennai 600006, India

<sup>e</sup> Department of Cardiology, Meittra Hospital, Calicut, Kerala 673005, India

<sup>f</sup> Sri Jayadeva Institute of Cardiovascular Sciences and Research, Jayanagar, Bengaluru 560041, India

<sup>g</sup> Sir H. N. Reliance Foundation Hospital and Research Centre, Girgaon, Mumbai, Maharashtra 400004, India

<sup>h</sup> Medanta, The Medicity Hospitals, Haryana 122001, India

<sup>i</sup> Fortis Escorts Heart Institute, New Delhi 110025, India

<sup>j</sup> Rajasthan Hospital Limited, Jaipur, Rajasthan 302018, India

<sup>k</sup> Sri Jayadeva Institute of Cardiovascular Sciences and Research, Mysuru, Karnataka 570016, India

<sup>l</sup> Madras Medical Mission Hospital, Chennai, Tamil Nadu 600037, India

<sup>m</sup> CÚRAM, SFI Research Centre for Medical Devices, H91 W2TY Galway, Ireland

<sup>n</sup> Narayana Institute of Cardiac Sciences, Bengaluru, Karnataka 560099, India

<sup>o</sup> Krishna Institute of Medical Sciences (KIMS), Hyderabad, Telangana 500014, India

<sup>p</sup> Narayana Hospital (NH), Ahmedabad, Gujarat 380023, India

<sup>q</sup> P S Govindaswami (PSG), Coimbatore 641004, India

<sup>r</sup> S. L. Raheja Hospital - Fortis, Mumbai, Maharashtra 400016, India

<sup>s</sup> Apollo Hospital, Navi Mumbai, Maharashtra 400614, India

<sup>t</sup> Max Hospital, Saket, New Delhi, Delhi 110017, India

<sup>u</sup> Sri Ramachandra Hospital (SRMC), Chennai, Tamil Nadu 600116, India

<sup>v</sup> William Harvey Research Institute, Queen Mary University of London and Barts Heart Centre, London EC1M 6BQ, UK

### ARTICLE INFO

#### Keywords:

Transcatheter aortic valve implantation  
Aortic regurgitation  
Videodensitometry  
Myval Octacor  
Balloon expandable valve

### ABSTRACT

**Background:** The balloon expandable Myval transcatheter heart valve (THV) showed encouraging results regarding residual aortic regurgitation (AR) from multiple observational studies. The newly designed Myval Octacor has been introduced recently, aiming for a reduction in AR and improved performance.

**Objectives:** The focus of this study is to report the incidence of AR using the validated quantitative Videodensitometry angiography technology (qLVOT-AR%) in the first in human use of the Myval Octacor THV system.

**Methodology:** We report on the first in human use of the Myval Octacor THV system in 125 patients in 18 Indian centres. Independent retrospective analysis of the final aortograms following implantation of the Myval Octacor

**Abbreviations:** AS, Aortic Stenosis; AV, Aortic Valve; AR, Aortic regurgitation; BE, Balloon-expandable.; PVL, Paravalvular Leakage; SE, Self-expandable; TAVI, Transcatheter Aortic Valve Implantation.

\* Corresponding author at: Discipline of Cardiology, Saolta Group, Galway University Hospital, Health Service Executive and CORIB Core Lab, University of Galway, Galway H91 TK33, Ireland.

E-mail address: [osama.soliman@universityofgalway.ie](mailto:osama.soliman@universityofgalway.ie) (O. Soliman).

<https://doi.org/10.1016/j.ijcard.2023.04.003>

Received 30 January 2023; Received in revised form 29 March 2023; Accepted 3 April 2023

Available online 5 April 2023

0167-5273/© 2023 The Author(s). Published by Elsevier B.V. This is an open access article under the CC BY license (<http://creativecommons.org/licenses/by/4.0/>).

was performed using the CAAS-A-Valve software. AR is reported as a regurgitation fraction. The previously validated cutoff values have been used to identify  $\geq$ moderate AR (RF%  $>17\%$ ), mild ( $6\% < \text{RF}\% \leq 17\%$ ), and none or trace AR (RF%  $\leq 6\%$ ).

**Results:** Final aortogram was analysable for 103 patients (84.4%) among the 122 available aortograms. 64 (62%) patients, had tricuspid aortic valve (TAV), 38 (37%) with bicuspid AV (BAV), and one with unicuspid AV. The median absolute RF% was 2% [1, 6], moderate or more AR incidence was 1.9%, mild AR in 20.4%, and none or trace AR in 77.7%. The two cases with RF%  $>17\%$  were in the BAV group.

**Conclusion:** The initial results of Myval Octacor using quantitative angiography-derived regurgitation fraction demonstrated a favourable outcome regarding residual AR, possibly due to improved device design. Results must be confirmed in a larger randomised study, including other imaging modalities.

## 1. Introduction

After 20 years of transcatheter aortic valve implantation (TAVI) practice, it becomes the standard of care treatment for severe degenerative aortic stenosis (AS) in patients older than 65–75 years, irrespective of the surgical risk [1,2]. Since the first TAVI case in April 2002 using the Cribier–Edwards aortic transcatheter valve [3], several TAVI devices have been developed, tested (In-vivo and in-vitro), and approved for use [4]. The different transcatheter heart valve (THV) designs and iterations have been tested for safety and efficacy in numerous randomised controlled trials (RCT) [5] in addition to multiple prospective non-randomised registries [6–8].

One of the known limitations of the first-generation TAVI devices, either self-expandable (SE) or balloon-expandable (BE), was the frequent mild and moderate or more residual paravalvular leakage (PVL) compared to surgical aortic valve replacement [9–11]. Some reports suggest the link between mild PVL and mortality, so the new target has been directed toward reducing or even eliminating mild PVL [12–14]. This has led the different manufacturers to adopt, among other improved characteristics, anti-PVL features in the redesigned next generation THV systems [5,15].

The recent generations of TAVI devices show design changes with the addition of active and larger internal and external sealing skirts and visible markers for better and controlled positioning, aiming not only for the elimination of significant PVL but also reduction of mild PVL [5]. Overall, the improved designs have been reported to reduce the PVL rate in several devices [5,15–18].

The redesigned Myval Octacor THV (Meril Life Sciences Pvt. Ltd. Vapi, Gujarat, India) is the new iteration of Myval THV that has been developed recently, including adding a new skirt size and design and the improved device frame design and cell shape. The new Myval Octacor THV has been newly implanted in a selected population indicated for TAVI in India. We thought to investigate the initial results of residual PVL by analysing the final procedural aortograms using the validated quantitative Videodensitometry technology [18–24] through an independent Core Laboratory analysis.

## 2. Methodology

This study comprised the first in human implantation of the Myval Octacor THV system in 125 Indian patients with severe AS in 18 Indian TAVI centres (Supplementary Table 1). TAVI treatment was based on the local heart team's decision at each participating centre.

Pre-procedural Echocardiography confirming the diagnosis of AS was performed and analysed locally in the sites according to the recommended guidelines of native valvular assessment. Pre-procedural multi-slice computed tomography scans (MSCT) were analysed by a Core Laboratory (MSCT Core Lab-Meril Life Sciences Pvt. Ltd., Vapi, Gujarat, India). Aortic valve leaflets (AVL) and left ventricle outflow tract (LVOT) calcifications were classified and graded using a semi-quantitative scoring system, as previously described [25].

Device size was selected as recommended for the Myval Octacor THV using the annulus area ( $\text{mm}^2$ ) and as recommended by the manufacturer (Supplementary fig. 1). Patients' baseline details were collected from

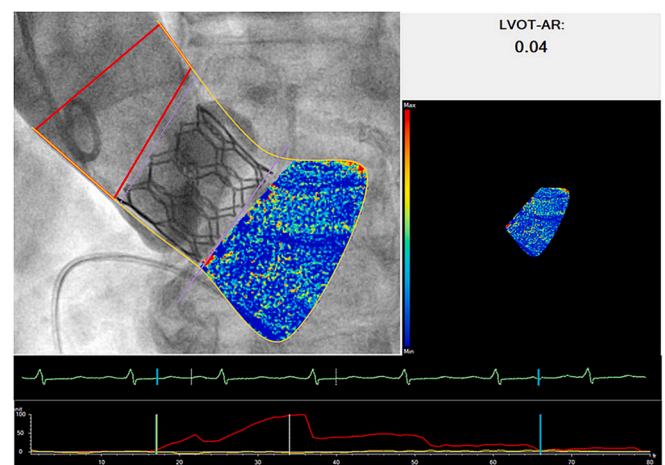
each site. Procedural TAVI angiograms and cine loops were shared with CORIB Core Lab for advanced research and cardiovascular imaging (University of Galway, Galway, Ireland) for independent analysis of the final aortic angiograms after implantation of the Myval Octacor with the quantitative Videodensitometry technology (qLVOT-AR) using CAAS-A-Valve 2.1.2 (PieMedical Imaging, The Netherlands), to assess the AR severity in the form of a regurgitant fraction (RF%) on a scale between 0 and 100% (Fig. 1). The previously validated cutoff values have been used to identify moderate or more A, (RF%  $>17\%$ ), mild ( $6\% < \text{RF}\% \leq 17\%$ ) and none or trace AR (RF%  $\leq 6\%$ ) [19–21]. Sellers' grading and depth of implantation were assessed as recommended [26].

The study was approved by the local ethics committee for each centre and complied with the Declaration of Helsinki.

### 2.1. Device description

Myval Octacor is the newly designed iteration of balloon-expandable (BE) Myval THV and is manufactured from nickel-cobalt alloy for optimal radial strength and radiopacity. The valve leaflets are manufactured using bovine pericardium tissue that is decellularized using Meril's proprietary Anti Calcium treatment. Myval Octacor has two rows of tessellating, geometrically identical octagonal cells as opposed to three rows of the predecessor Myval THV, but with the same frame height (17.35–21.14 mm) (See Fig. 2). This design change might reduce the foreshortening of the Myval Octacor THV during expansion and facilitates deployment accuracy)

The upper row (Outflow) is designed with large open cell octagons (6 mm) aiming for an uninterrupted flow and access to coronary arteries, while the lower row (Inflow) cells are closed with polyethylene terephthalate (PET) as a fabric puncture resistance internal skirt (50% of the frame height) in addition to a higher circumferential external skirt without much slack and increased surface contact with the surrounding



**Fig. 1.** Quantitative AR analysis of the Aortography using the CAAS-A-Valve software after implantation of the Myval Octacor transcatheter heart valve, AR quantification is presented as LVOT-AR (regurgitant fraction, (RF%)).

anatomy to plug micro-channels, and to reduce the propensity for PVLs (Fig. 2). The Navigator Inception THV delivery system has an additional landing zone marker toward the ventricular end that facilitates precise positioning of Myval Octacor THV at the annulus.

The new Myval Octacor is available in the same conventional sizes (20, 23, 26 and 29 mm), in addition to the novel intermediate sizes (21.5, 24.5 and 27.5 mm), and XL sizes (30.5 and 32 mm).

## 2.2. Oversizing ratio

Oversizing was calculated based on the native annulus measured area from MSCT, and using the manufacturer provided nominal THV area for each size (Supplementary table 2), the range of native annulus for each size is summarised in Supplementary fig. 1.

The following formula was used for calculation.

Oversizing ratio = (Nominal THV area-mm<sup>2</sup>/ Native annulus (MSCT) area-mm<sup>2</sup>-1) \*100, as previously described [27].

## 2.3. Statistical analysis

Continuous variables are reported as mean and standard deviation

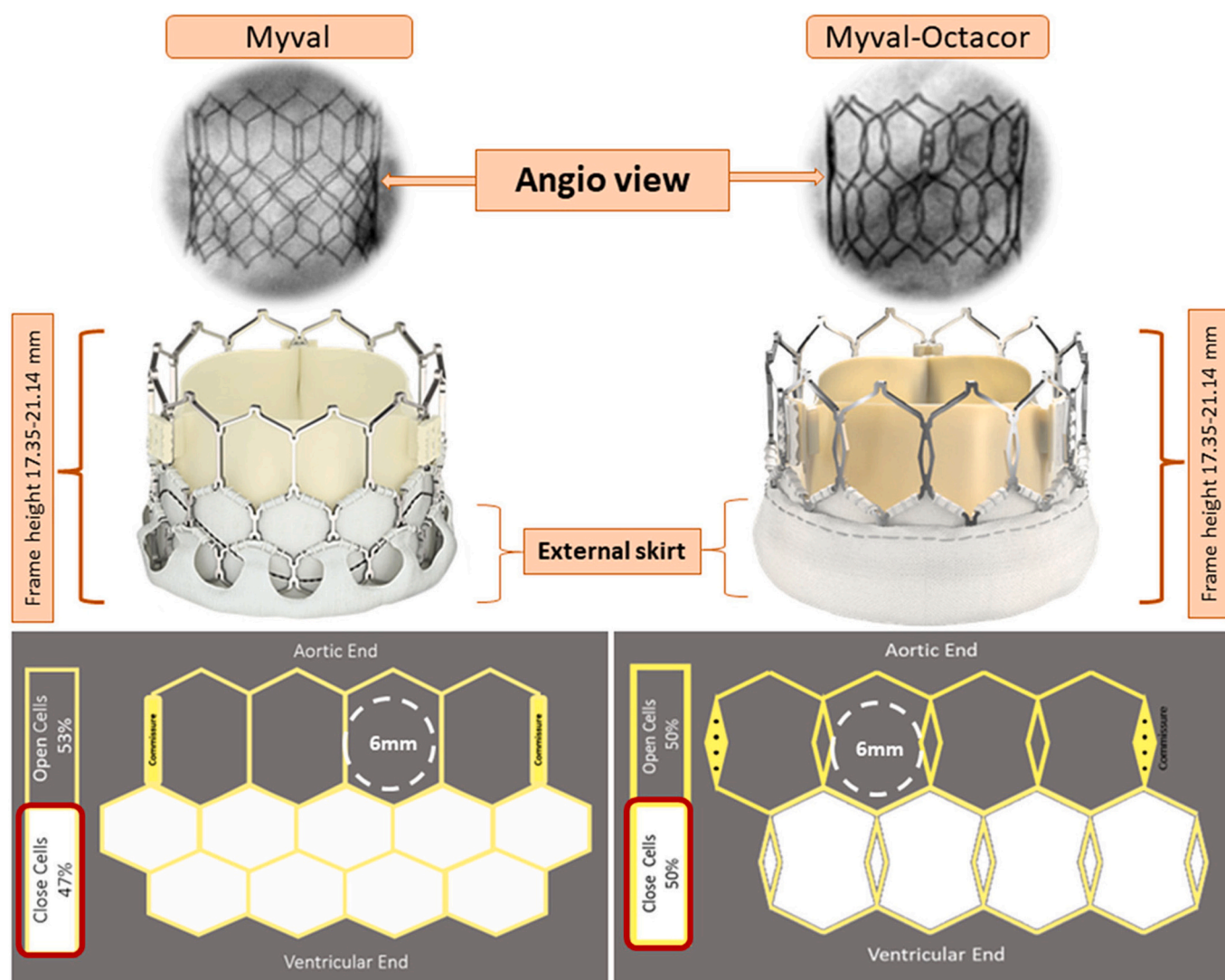
(SD) or median and interquartile range [IQR] according to the data distribution. Categorical variables are reported as frequency and percentage. The Bayesian ordinal regression models assessed the association between qLVOT-AR and independent variables. The cumulative link function was used to fit the regression model to ordered response variables. The associations were considered statistically significant when the posterior 95% credible interval (CrI) for beta covered 0. The rstan, brms, and ggplot2 packages in R 4.1.3 environment were used to conduct the Bayesian ordinal regression models. In addition, another statistical analysis was performed using IBM®SPSS® version 27 (IBM Corp. in Armonk, NY, USA).

A random sample of 15 cases was selected to test Inter, and intra-observer variability was tested using the Interclass correlation coefficient and Bland-Altman Analysis.

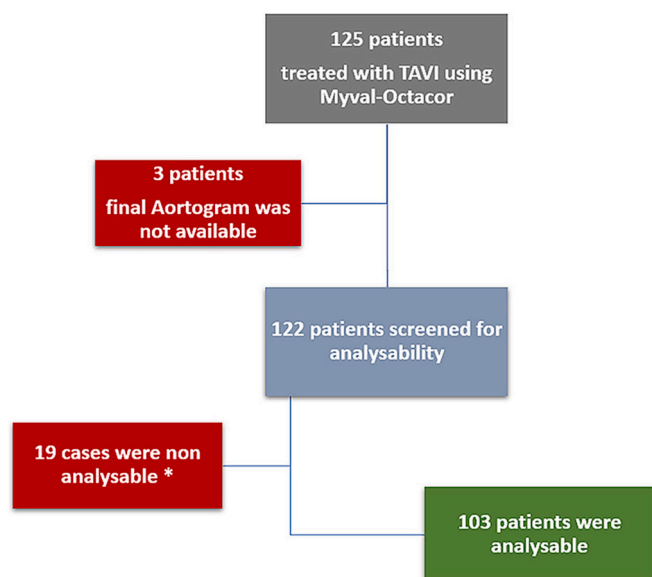
## 3. Results

### 3.1. Patients' baseline characteristics

Among 125 patients with severe symptomatic AS treated with TAVI using Myval Octacor THV between July 2021 and June 2022. Final



**Fig. 2.** Difference in design between the first Myval generation and the new Myval Octacor transcatheter heart valves, Top-left; Angio view of the Myval THV, Top-right; the angio view of the Myval Octacor; mid-left; Myval THV, mid-right; Myval Octacor THV, lower-left; cell design of Myval THV stent frame, three rows of hexagonal cells with large upper one 6 mm in diameter, lower-right; cells design of the Myval Octacor THV stent frame, two rows of identical octagonal cells, 6 mm in diameter.



**Fig. 3.** Flow chart of the study including patients' and aortograms included in the study.

Aortograms were available for 122, with 103 (84.4%) analysable (See Fig. 3).

The mean age was  $69.9 \pm 8.9$  years, 66 (64%) were males, the median STS risk score was 3.47% [2.15, 7.11], and the majority were symptomatic with NYHA class III/IV (84%) (Table 1). Pre-procedural echocardiography revealed a median effective orifice area (EOA) of 0.6 [0.5, 0.8] cm<sup>2</sup> and mean pressure gradient of 47.5 [40, 59.5] mmHg (Table 2). Pre-procedural MSCT scan analysis showed that 64 (62%) of

**Table 1**  
Patients' baseline characteristics.

Characteristic	
Age, Years	69.9 (8.9)
Sex	
Male	66 (64%)
Female	37 (36%)
Patients' size	
Weight, Kg	64.4 (12.4)
Height, cm	160 (8.7)
BSA, m <sup>2</sup>	1.69 (0.18)
BMI, kg/m <sup>2</sup>	25.20 (4.7)
Serum Creatinine, mg/dl	1.2 (0.8)
STS risk score, %	3.47 [2.15, 7.11]
Diabetes mellitus	52 (57%)
Systemic hypertension	59 (64.8%)
Coronary artery disease	48 (54)
Prior myocardial infarction	5 (5.7%)
Prior PCI	8 (9.0%)
Prior CABG	12 (13.5%)
Chronic kidney disease	11 (12.5%)
Prior haemodialysis	1 (1.2%)
Chronic obstructive pulmonary disease	12 (13.3%)
Prior (any) valve surgery	6 (6.5%)
Mitral valve replacement	5 (4.8%)
Tricuspid valve repair	2 (1.9%)
Peripheral vascular disease	3 (3.4%)
Cerebrovascular disease	4 (4.5%)
Any neoplasm (past or active)	2 (2.3%)
Prior pacemaker	6 (6.7%)
New York Heart Association class (NYHA)	
Class II	19 (18.5%)
Class III	53 (51.5%)
Class IV	31 (30%)

Data are presented as Mean (SD), Median [IQR], and numbers with (frequency %).

CABG: coronary artery bypass graft; PCI: percutaneous coronary intervention.

**Table 2**

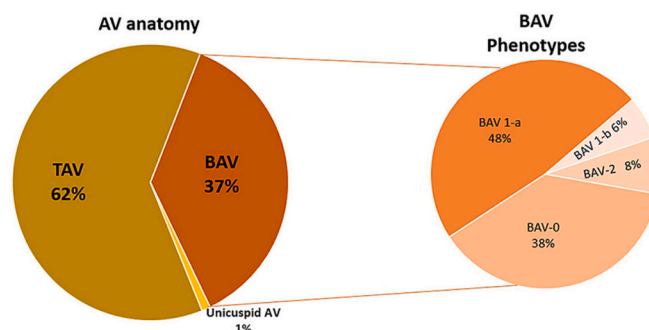
Baseline Echocardiographic and pre-TAVI MDCT assessment.

Echocardiography	
Aortic valve EOA, cm <sup>2</sup>	0.6 [0.5, 0.8]
Mean pressure gradient, mmHg	47.5 [40, 59.5]
Peak pressure gradient, mmHg	77 [68, 94.7]
Peak transvalvular velocity, m/s	4.3 [4, 4.9]
Left ventricle EF, %	51 [43.5, 60]
Moderate/Severe aortic regurgitation	31 (33%)
Moderate/Severe mitral regurgitation	11 (12.4%)
Moderate/Severe tricuspid regurgitation	14 (14%)
MSCT (essential assessment)	
Aortic valve anatomy	N = 103
Tricuspid	64 (62%)
Bicuspid	38 (37%)
Unicuspid	1 (1%)
Bicuspid phenotypes (Sievers' classification)	N = 38
Type 0	14 (36.8%)
Type 1-a	19 (50%)
Type 1-b	2 (5.3%)
Type 2	3 (7.9%)
Aortic annulus area, mm <sup>2</sup>	434.8 (99)
Aortic annulus-area derived diameter, mm	23.4 (2.6)
LVOT average diameter, mm	23.8 (3.1)
RCA height, mm	15.5 (3.1)
LCA height, mm	13.3 (4.4)
Sino-tubular junction average diameter, mm	28.7 (5.0)
Calcium volume (contrast-enhanced derived), mm <sup>3</sup>	477 [246, 1029]
Aortic valve leaflets calcification severity grading	
None	1 (1%)
Mild	43 (44.3%)
Moderate	30 (31%)
Severe	23 (23.7%)
LVOT calcification	
None	64 (66%)
Mild	23 (23.7%)
Moderate	6 (6.2%)
Severe	4 (4.1%)
Aortic angulation	
Horizontal ( $\geq 49^\circ$ )	36 (37%)
Vertical ( $< 49^\circ$ )	61 (63%)

Data are presented as Mean (SD), Median [IQR], and numbers with (frequency %).

EF: ejection fraction, EOA: effective orifice area, LCA: left coronary artery, LVOT: left ventricular outflow tract, RCA: right coronary artery.

patients have tricuspid AV (TAV) anatomy, 38 (37%) have bicuspid AV (BAV) and one patient with unicuspid AV (Fig. 4). According to Sievers' classification, all BAV phenotypes were reported (Table 2). The mean aortic annulus area and area-derived diameters were  $434.8 \pm 99$  mm<sup>2</sup> and,  $23.4 \pm 2.6$  mm, respectively (Table 2). Assessment of the calcium burden severity revealed moderate/severe AVL calcifications in 54.7% and LVOT moderate/severe calcifications in 10.3%. The horizontal aorta was observed in 37% of patients (Table 2).



**Fig. 4.** Aortic valve anatomy with the prevalence of each aortic valve phenotype.



### 3.2. Procedural characteristics

All patients were operated through transfemoral access (100%) across the expandable 14Fr Python introducer sheath (Meril Life Sciences Pvt. Ltd. Vapi, Gujarat, India) and using the newly designed Navigator Inception THV delivery system (Meril Life Sciences Pvt. Ltd. Vapi, Gujarat, India).

Balloon pre-dilatation was performed in 61 (59.2%), and balloon post-dilatation in 13 (12.6%) (Table 3). Seven different sizes of the Myval Octacor THV were used; the novel intermediate sizes with a 1.5 mm increment from the standard sizes (21.5, 24.5, and 27.5 mm) were used in 49 (47.6%) patients.

### 3.3. Oversizing ratio

The calculation revealed that the median of down/oversizing was 7.7 [3, 10.9], while oversizing was achieved in 93 (90.3%) with a median of 8.2% [3.8, 11.5].

**Table 3**  
Essential procedural characteristics.

Characteristic	N = 103
Transfemoral vascular access	103 (100%)
Implanted Myval Octacor sizes	
20 mm	8 (7.8%)
21.5 mm	20 (19.4)
23 mm	24 (23.3%)
24.5 mm	18 (17.5%)
26 mm	14 (13.6%)
27.5 mm	10 (9.7%)
29 mm	9 (8.7%)
Balloon pre-dilatation	61 (59.2%)
Balloon post-dilatation	13 (12.6%)
Independent Core Lab analysis of the final aortograms	
Procedural visual AR (Sellers' grade)	
Grade 0	57 (55.3%)
Grade I	44 (42.7%)
Grade II	1 (1.0%)
Grade III	1 (1.0%)
Grade IV	0
Device implantation depth-LCC, mm	4.1 [3.3, 4.9]
Device implantation depth-NCC, mm	4.1 [3.3, 5.1]
q-LVOT AR, RF%	
All patients	2 [1, 6]
Tricuspid AV	2 [1, 6]
Bicuspid AV	2.5 [1, 6]
Down/Oversizing ratio (%)	
(THV nominal area and native annulus area, mm <sup>2</sup> )	
below -5%	1 (1%)
between -4% and 0%	9 (8.7%)
between 1% and 5%	33 (32%)
between 6% and 10%	29 (28.2%)
between 11% and 20%	29 (28.2%)
>20%	2 (1.9%)
q-LVOT AR grading	
All patients	
Non/trace AR	80 (77.7%)
Mild AR	21 (20.4%)
Moderate or more AR	2 (1.9%)
Tricuspid AV	N = 64
Non/trace AR	51 (79.7%)
Mild AR	13 (20.3%)
Moderate or more AR	0
Bicuspid AV	N = 38
Non/trace AR	28 (73.7%)
Mild AR	8 (21%)
Moderate or more AR	2 (5.3%)
Unicuspid AV	N = 1
Non/trace AR	1

Data are presented as Mean (SD), Median [IQR], and numbers with (frequency %).

AR: aortic regurgitation, AV: aortic valve, q-LVOT AR: quantitative LVOT aortic regurgitation, THV: transcatheter heart valve.

Oversizing was  $\leq 10\%$  in 60.2% of patients, and 28.2% were between 10% and 20%, Table 3.

Downsizing with  $-15\%$  was observed in one case of BAV type 0 with smaller supra-annular measurement (Trapezoid valve configuration).

### 3.4. Core Lab analysis of the final aortograms

The final aortogram after implantation of Myval Octacor was analysed independently and Sellers' grade [26] was assessed for all cases; the majority of them were graded as 0 and 1, 55.3% and 42.7%, respectively. Implantation depth at left coronary (LCC) and non-coronary (NCC) cusps were analysable in 78 cases with a median of 4.1 [3.3, 4.9] and 4.1 [3.3, 5.1], respectively.

Objective quantitative angiography of AR (q-LVOT-AR) was analysable in 103 (84.4%) of cases, with the median absolute value of RF% being 2% [1.0, 6.0] and a standard error of 0.4% (Fig. 4).

The causes of non-analysability, Sellers' grading, and baseline and procedural characteristics of the 19 non-analysable cases are summarised in supplementary Table 3.

According to the validated cut-off values of qLVOT-AR [19–21], the analysis showed that 77.7% with RF of  $\leq 6\%$ , which indicates none/trace AR, 20.4% with  $6\% < RF \leq 17\%$  which indicates mild AR, and 1.9% with  $RF > 17\%$  which indicates moderate or more AR, with maximum RF % of 19%.

### 3.5. Residual AR in tricuspid vs bicuspid anatomy

The median of absolute RF% value between TAV and BAV was 2.0 [1, 6] and 2.5 [1, 6], respectively, and none/trace, mild and  $\geq$  moderate AR was 79.7%, 20.3% and 0% vs 73.7, 21% and 5.3% respectively (Fig. 5). The Bayesian ordinal regression models showed a non-significant association between AV leaflet's anatomy and qLVOT AR severity (beta  $-0.355$ , 95% CrI  $[-1.29, 0.60]$ ).

### 3.6. The Bayesian ordinal regression model

We observed a statistically significant association between q-LVOT AR% and severe AVL calcification (Beta = 1.23, 95% CrI: 0.064, 02.42). The association between q-LVOT AR% and the rest of the variables was insignificant (Supplementary Table 4).

### 3.7. Inter-observer and intra-observer variability

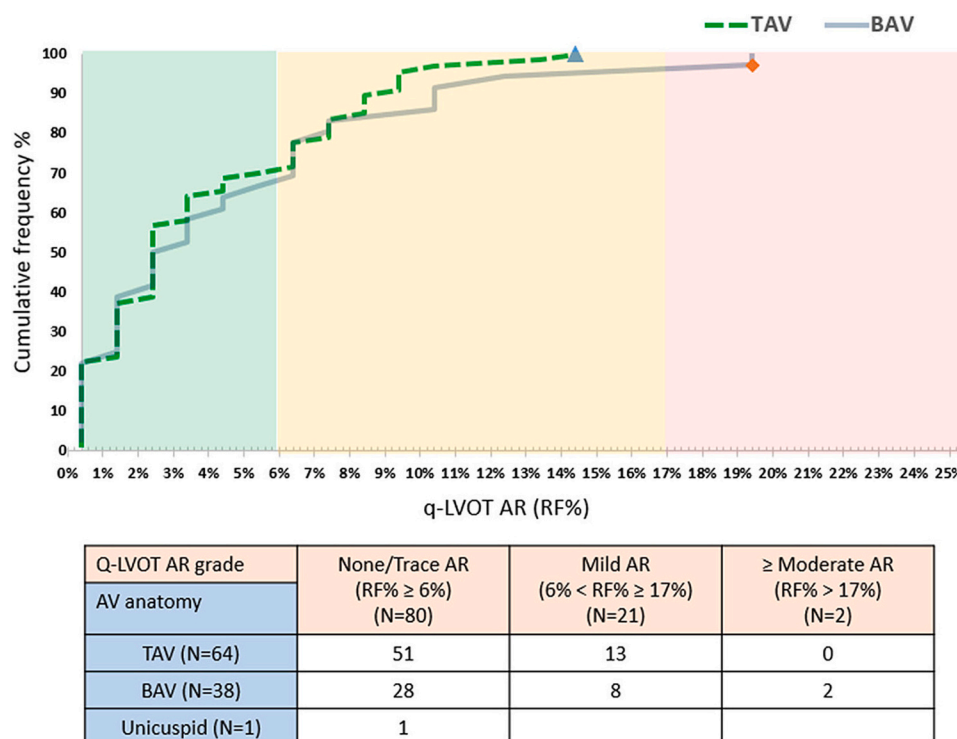
Inter-observer variability (ICC = 0.92, 95% CI 0.78–0.97) and intra-observer variability (ICC = 0.97, 95% CI 0.93–0.99) of qLVOT-AR showed excellent reproducibility of the analysis (Supplementary Fig. 2).

Bland-Altman analysis for Inter-observer variability showed limits of agreement between  $-2.44$  (95% CI  $-4.46, -0.40$ ) and  $5.77$  (95% CI  $3.74-7.79$ ) with average bias  $1.67$  (95% CI  $0.51-2.82$ ), and for intra-observer variability showed limits of agreement between  $-1.67$  (95% CI  $-2.99 - -0.35$ ) and  $3.67$  (95% CI  $2.35-4.99$ ) with average bias  $1.0$  (95% CI  $0.25-1.76$ ) (Supplementary Fig. 2).

## 4. Discussion

This is the first study to report the post-TAVI residual AR after implantation of the newly designed BE Myval Octacor THV system. AR was analysed using the quantitative Videodensitometry technology from the final post-procedural aortograms. The essential results of this study are 1) the incidence of none/trace, mild and  $\geq$  moderate AR is 77.7%, 20.4% and 1.9%, respectively, 2) the median absolute RF% value is 2%, 3) the prevalence of BAV in the study cohort was 37%, and 4) no significant difference between the AR severity between tricuspid and bicuspid (All phenotypes) anatomy regarding residual AR severity.

According to the qLVOT-AR results, Myval Octacor THV shows a momentous reduction of the significant post-TAVI AR comparable to the



**Fig. 5.** Cumulative curve of the quantitative AR analysis results of patients with tricuspid (dotted green line) and bicuspid aortic valve (Grey line). (For interpretation of the references to colour in this figure legend, the reader is referred to the web version of this article.)

best in a class of the new THV generations (either SE or BE) analysed using the same technology [18].

The Myval Octacor is the 2nd generation of the Myval BE THV with considerable changes from its predecessor design; this includes the anti-PVL new skirt design comprising one internal lining (completely cover), the lower cells row with 3% more extension and outer larger PET fabric skirt allowing more contact with the surrounding annular anatomy and plug micro-channels to reduce the propensity for PVLs (Fig. 2).

In comparison to other BE THVs, Sapien3™ (Edwards Life science, USA), (N = 397) previously reported against the first generation Myval [28], Myval Octacor (N = 103) showing more reduction of moderate/severe AR rate (1.9% vs 8.3%) [28]. However, the last iteration of Sapien3™ Ultra still needs to be analysed with the same technology, but initial reports confirmed the reduction of significant and mild AR using the conventional transthoracic echocardiography [16].

The favourable acute performance of the Myval Octacor regarding AR severity rates is very assuring considering the morpho-anatomic characteristic and demographic of this population which include the relatively young and low surgical risk population with a mean age of 69.9 years and median STS score of 3.47%. Among the analysed cases, 54.7% have moderate or severe AV leaflets (AVL) calcification and 34% with mild or more LVOT calcifications. Accordingly, the rate of balloon pre-dilatation was 59.2%, while the balloon post-dilatation performed at only 12.6%. Furthermore, one-third of the population had bicuspid AS.

Myval Octacor was implanted in 39 non-tricuspid AV (38 BAV and interestingly in one unicuspid AV) with analysable qLVOT-AR; only two patients showed moderate AR with qLVOT-AR (RF%) of 19%. Except for those two cases (1.9%), post-TAVI residual AR was either absent or mild, which is very encouraging and could be explained by the improved design feature of the Myval Octacor.

The new design has the same frame height as the previous Myval iteration (17.35–21.14 mm) but with only two rows of identical octagonal cells. This reduces the foreshortening of the Myval Octacor THV during expansion and facilitates deployment accuracy. With the new Octacor design, the expected infra-annular implantation depth ranges

between 2.95 and 3.60 mm, which might be targeting a lower incidence of pacemaker implantation rate (this was not tested in this study).

The median depth at both left and right coronary cusps with 4.1 mm, and the association between implantation depth and AR severity was nonsignificant (Supplementary table 2).

Another potential mechanism for the Myval THV system's improved performance is the availability of intermediate sizes (21.5, 24.5 and 27.5 mm) with only a 1.5 mm difference instead of 3 mm of the conventional sizes (20, 23, 26 and 29 mm). In a previous report by Kawashima et al., the utilisation rate of intermediate sizes was 42% of a large (>1000 patients) cohort treated with TAVI using the first generation Myval [29]. In our report, 47.6% of patients were treated with intermediate sizes of Myval Octacor, which might contribute to the promising results through avoidance of over-or downsizing in patients with borderline annular measurements, but this needs more specific investigations to confirm the utility of new sizes.

Oversizing of BE THVs has been reported as feasible and recommended within the safe ranges to minimise the incidence of PVL [30]. The calculated oversizing ratio with Myval Octacor revealed a median of 8.2% within the accepted range of <10%.

Among TAVI devices previously analysed using qLVOT-AR technology, SE ACURATE neo2 (N = 120) (Boston Scientific) and the Lotus (N = 546) (Boston Scientific) (not available in the market anymore) were at the top of the rank, followed by the first generation Myval with the incidence of moderate/severe AR was 1.7%, 2.2% and 2.8% respectively. Accordingly, Myval Octacor can be considered the 2nd in rank by only 1.9% of moderate/severe AR.

The recent reports demonstrated the association of mild PVL with mortality [12–14]. In addition to the considered extension of TAVI into the younger population and the increasing appetite/need for TAVI in bicuspid AS, the so-called “mild” PVL is becoming more relevant. After the noticeable reduction of significant AR with new THV generations (BE and SE), the TAVI ship rudder is directed toward the mild AR.

In this analysis, mild AR was reported in 20% of patients with a remarkable shift toward none/trace AR at 78%; compared to the

previous Myval iteration, mild was 47%, and none/trace was 50% [28].

This report represents the initial results (interim analysis) of Myval Octacore implantation in the real world, using qLVOT-AR technology to assess the residual AR; with such encouraging results, more reports are expected to be released soon using the TTE assessment and clinical outcomes.

Furthermore, the Myval Octacore THV system is being used in Europe in the COMPARE TAVI trial cohort B (NCT04443023), in which patients are randomly assigned to either Myval or Sapien3 THVs; in addition, it will be included in the LANDMARK trial [31] (NCT04275726), in which patients are randomly assigned to either Myval, Sapien3, or Evolut Pro THV series, with the inclusion of patients with BAV. However, while the results of this study are reassuring, they need to be confirmed in the aforementioned ongoing studies.

#### 4.1. Limitations

The current study has limitations, including the retrospective design of the study. In addition, the study comprised selected populations from one geographic area. We did not report clinical outcomes as our focus is exclusively on testing the impact of the newly designed Myval Octacore in mitigating residual AR, in line with the recent report of mortality associated with mild AR.

Notably, the demographics and morpho-anatomic characteristics, based on the detailed pre-TAVI CT scan analysis of the patient population, assure the patient selection that included more than one-third of bicuspid AS, younger age and significant aortic calcification.

#### 5. Conclusion

The initial results and experience from real-world implantation of the newly designed Myval Octacore THV system in selected patients with severe AS favourable outcomes regarding residual AR using the validated Videodensitometric quantitative technology. The results are encouraging regarding the reduction of moderate or more AR, in addition to the significant shift from mild to none or trace, thanks to the improved skirt size, design, and radiopaque markers that allow precise implantation depth. These acute results need to be confirmed with other imaging modalities and in a prospective randomised clinical trial.

Supplementary data to this article can be found online at <https://doi.org/10.1016/j.ijcard.2023.04.003>.

#### Authors contribution

Conceptualisation (Ahmed Elkoumy, Osama Soliman, Patrick Serruys, and Andreas Baumbach), formal analysis of (Ahmed Elkoumy, Mahmoud Abdelshafy), Supervision (Osama Soliman and Patrick Serruys), Statistical analysis (Shahram Arsang and Ahmed Elkoumy), Investigations (John Jose, Sengottuvelu Gunasekaran, Asish Kumar, B C Srinivas, C N Manjunath, K.S Ravindranath, Maulik Parekh, Praveen Chandra, Rajneesh Kapoor, Ashok Seth, Praveer Agrawal, Atul Mathur, Ravindra Singh Rao, Sadanada K S, Vijay Kumar, Sanjay Mehrotra, Bagirath Raghuraman, Uday Khanolkar, Rajendra Kumar Premchand, Manik Chopra, Prem Krishna, Hareesh Mehta, Rahul Gupta, Viveka Kumar, Nagendra Boopathy Senguttuvan), methodology (Ahmed Elkoumy and Osama Soliman), software (Ahmed Elkoumy), Data curation (Ahmed Elkoumy), Validation (Osama Soliman), writing the original draft (Ahmed Elkoumy and Osama Soliman), reviewing (Osama Soliman, Patrick Serruys), all authors have read and agreed to the published version of the manuscript.

#### Ethics and patients consent

The study has been approved by the Prime Independent Ethics Committee (Registration No.: ECR/366/Indt/GJ/2022).

All patients from all participating centres have provided formal informed consent accepting TAVI performance with the new Myval Octacore device, in addition to using the pseudo anonymised clinical and imaging data for scientific publications.

All participating centres have submitted local ethical approval.

#### Funding

This work has been conducted as a part of an institutional research grant supported by Meril Life Sciences Pvt. Ltd. Vapi, Gujarat, India.

The industry was not involved in the study design, analysis, data interpretation, writing of the article, or decision of submission for publication.

#### Declaration of Competing Interest

Ashok Seth serves as an Advisory Board Member/Speaker's bureau/received consulting honoraria from Abbott Vascular, Medtronic, Boston Scientific, and Meril Life Sciences; Sengottuvelu Gunasekaran serves as a proctor for Myval and has received honoraria from Meril Life sciences. Andreas Baumbach reports grants from Abbott Vascular, personal fees from Pi-Cardia, personal fees from Sinomed, and personal fees from Astra Zeneca, outside the submitted work; Patrick Serruys reports personal fees from SMT, Philips/Volcano, Xeltis, Novartis, and Meril life. Osama Soliman reports institutional research grants, including several industry-sponsored Core Lab activities. All other authors have no conflict of interest to declare.

#### Acknowledgement

We thank the Meril Life Sciences coordination team for data collection and MSCT Core Lab-Meril Life Sciences Pvt. Ltd., Vapi, Gujarat, India team for the detailed CT analyses.

#### References

- [1] A. Vahanian, F. Beyersdorf, F. Praz, M. Milojevic, S. Baldus, J. Bauersachs, D. Capodanno, L. Conradi, M. De Bonis, R. De Paulis, et al., ESC/EACTS Guidelines for the management of valvular heart disease, *Eur. Heart J.* 2021 (2021), <https://doi.org/10.1093/eurheartj/ehab395>.
- [2] C.M. Otto, R.A. Nishimura, R.O. Bonow, B.A. Carabello, J.P. Erwin 3rd, F. Gentile, H. Jneid, E.V. Krieger, M. Mack, C. McLeod, et al., 2020 ACC/AHA guideline for the management of patients with valvular heart disease: a report of the American College of Cardiology/American Heart Association Joint Committee on Clinical Practice Guidelines, *J. Am. Coll. Cardiol.* 77 (2021) e25–e197, <https://doi.org/10.1016/j.jacc.2020.11.018>.
- [3] A. Cribier, H. Eltchaninoff, A. Bash, N. Borenstein, C. Tron, F. Bauer, G. Derumeaux, F. Anselme, F. Laborde, M.B. Leon, Percutaneous transcatheter implantation of an aortic valve prosthesis for calcific aortic stenosis: first human case description, *Circulation*. 106 (2002) 3006–3008, <https://doi.org/10.1161/01.cir.0000047200.36165.b8>.
- [4] M. Chiarito, A. Spirito, J. Nicolas, A. Selberg, G. Stefanini, A. Colombo, B. Reimers, A. Kini, S.K. Sharma, G.D. Dangas, et al., Evolving devices and material in transcatheter aortic valve replacement: what to use and for whom, *J. Clin. Med.* (2022) 11, <https://doi.org/10.3390/jcm11154445>.
- [5] G. Santangelo, A. Ielasi, M. Pellicano, A. Latib, M. Tespili, F. Donatelli, An update on new generation transcatheter aortic valves and delivery systems, *J. Clin. Med.* (2022) 11, <https://doi.org/10.3390/jcm11030499>.
- [6] S. Cannata, C. Gandolfo, F.L. Ribichini, N. van Mieghem, S. Buccheri, M. Barbanti, S. Berti, R.C. Teles, A.L. Bartorelli, G. Musumeci, et al., One-year outcomes after transcatheter aortic valve implantation with the latest-generation SAPIEN balloon-expandable valve: the S3U registry, *EuroIntervention*. (2023), <https://doi.org/10.4244/EIJ-D-22-01022>.
- [7] Y. Ahmad, J.P. Howard, A.D. Arnold, M.V. Madhavan, C.M. Cook, M. Alu, M. J. Mack, M.J. Reardon, V.H. Thourani, S. Kapadia, et al., Transcatheter versus surgical aortic valve replacement in lower-risk and higher-risk patients: a meta-analysis of randomized trials, *Eur. Heart J.* 44 (2023) 836–852, <https://doi.org/10.1093/eurheartj/ehac642>.
- [8] S. Lars, S.W. Antony, G.W. Stephen, S. Dave, C. Bassem, M. Ganesh, Y. Gerald, B. Francesco, B. Nicholas, J.R. Michael, Thirty-day and one-year outcomes of the Navitor transcatheter heart valve in patients with aortic stenosis: the prospective, multicentre, global PORTICO NG study, *EuroIntervention* (2023), <https://doi.org/10.4244/EIJ-D-22-01108> online publish-ahead-of-print.
- [9] J.J. Popma, G.M. Deeb, S.J. Yakubov, M. Mumtaz, H. Gada, D. O'Hair, T. Bajwa, J. C. Heiser, W. Merhi, N.S. Kleiman, et al., Transcatheter aortic-valve replacement

- with a self-expanding valve in low-risk patients, *N. Engl. J. Med.* 380 (2019) 1706–1715, <https://doi.org/10.1056/NEJMoa1816885>.
- [10] M.B. Leon, C.R. Smith, M.J. Mack, R.R. Makkar, L.G. Svensson, S.K. Kodali, V. H. Thourani, E.M. Tuzcu, D.C. Miller, H.C. Herrmann, et al., Transcatheter or surgical aortic-valve replacement in intermediate-risk patients, *N. Engl. J. Med.* 374 (2016) 1609–1620, <https://doi.org/10.1056/NEJMoa1514616>.
  - [11] M.J. Reardon, N.M. Van Mieghem, J.J. Popma, N.S. Kleiman, L. Sondergaard, M. Mumtaz, D.H. Adams, G.M. Deeb, B. Maini, H. Gada, et al., Surgical or transcatheter aortic-valve replacement in intermediate-risk patients, *N. Engl. J. Med.* 376 (2017) 1321–1331, <https://doi.org/10.1056/NEJMoa1700456>.
  - [12] T. Okuno, D. Tomii, D. Heg, J. Lanz, F. Praz, S. Stortecky, D. Reineke, S. Windecker, T. Pilgrim, Five-year outcomes of mild paravalvular regurgitation after transcatheter aortic valve implantation, *EuroIntervention.* 18 (2022) 33–42, <https://doi.org/10.4244/EIJ-D-21-00784>.
  - [13] S. Schoechlin, M. Hein, T. Brennemann, M. Eichenlaub, U. Schulz, N. Jander, F. J. Neumann, 5-year outcomes after transcatheter aortic valve implantation: focus on paravalvular leakage assessed by echocardiography and hemodynamic parameters, *Catheter. Cardiovasc. Interv.* 99 (2022) 1582–1589, <https://doi.org/10.1002/ccd.30083>.
  - [14] H. Yokoyama, Y. Sugiyama, H. Miyashita, M. Jalanko, T. Ochiai, K. Shishido, F. Yamanaka, T. Vahasila, S. Saito, M. Laine, et al., Impact of mild paravalvular regurgitation on long-term clinical outcomes after transcatheter aortic valve implantation, *Am. J. Cardiol.* 191 (2023) 14–22, <https://doi.org/10.1016/j.amjcard.2022.12.002>.
  - [15] O.M. Rotman, M. Bianchi, R.P. Ghosh, B. Kovarovic, D. Bluestein, Principles of TAVR valve design, modelling, and testing, *Expert Rev Med Dev.* 15 (2018) 771–791, <https://doi.org/10.1080/17434440.2018.1536427>.
  - [16] C. Pellegrini, T. Rheude, M. Renker, A. Wolf, J.M. Wambach, H.A. Alvarez-Covarrubias, O. Dorr, P. Singh, E.I. Charitos, E. Xhepa, et al., ACURATE neo2 versus SAPIEN 3 ultra for transcatheter aortic valve implantation, *EuroIntervention.* (2022), <https://doi.org/10.4244/EIJ-D-22-00164>.
  - [17] S. Baggio, M. Pagnesi, W.K. Kim, A. Scotti, M. Barbanti, G. Costa, M. Adamo, R. Komowski, H. Vaknin-Assa, R. Estevez-Loureiro, et al., Comparison of transcatheter aortic valve replacement with the ACURATE neo2 versus Evolut PRO/PRO+ devices, *EuroIntervention.* (2022), <https://doi.org/10.4244/EIJ-D-22-00498>.
  - [18] M. Abdelshafy, P.W. Serruys, W.-K. Kim, A. Rück, R. Wang, L. Tao, A. Elkoumy, H. Elzomor, S. Garg, Y. Onuma, et al., Quantitative angiographic assessment of aortic regurgitation following 11 TAVR devices: an update of a multicenter pooled analysis, *J. Soc. Cardiovasc. Angiogr. Interv.* (2022) 1, <https://doi.org/10.1016/j.jscai.2022.100037>.
  - [19] M. Abdelghani, H. Tateishi, Y. Miyazaki, R. Cavalcante, O.I.I. Soliman, J.G. Tijssen, R.J. de Winter, J. Baan Jr., Y. Onuma, C.M. Campos, et al., Angiographic assessment of aortic regurgitation by video-densitometry in the setting of TAVI: echocardiographic and clinical correlates, *Catheter. Cardiovasc. Interv.* 90 (2017) 650–659, <https://doi.org/10.1002/ccd.26926>.
  - [20] H. Tateishi, M. Abdelghani, R. Cavalcante, Y. Miyazaki, C.M. Campos, C. Collet, L.B. Slots, R.S. Leite, J.A. Mangione, A. Abizaid, et al., The interaction of de novo and pre-existing aortic regurgitation after TAVI: insights from a new quantitative aortographic technique, *EuroIntervention.* 13 (2017) 60–68, <https://doi.org/10.4244/EIJ-D-16-00647>.
  - [21] M. Abdel-Wahab, M. Abdelghani, Y. Miyazaki, E.W. Holy, C. Merten, D. Zachow, P. Tonino, M.C.M. Rutten, F.N. van de Vosse, M.A. Morel, et al., A novel angiographic quantification of aortic regurgitation after TAVR provides an accurate estimation of regurgitation fraction derived from cardiac magnetic resonance imaging, *JACC Cardiovasc Interv.* 11 (2018) 287–297, <https://doi.org/10.1016/j.jcin.2017.08.045>.
  - [22] M. Abdelghani, Y. Miyazaki, E.S. de Boer, J.P. Aben, M. van Sloun, T. Suchecki, M. van 't Veer, O. Soliman, Y. Onuma, R. de Winter, et al., Videodensitometric quantification of paravalvular regurgitation of a transcatheter aortic valve: in vitro validation, *EuroIntervention.* 13 (2018) 1527–1535, <https://doi.org/10.4244/EIJ-D-17-00595>.
  - [23] Y. Miyazaki, R. Modolo, H. Tateishi, P.W. Serruys, Acute performance of first- and second-generation transcatheter aortic valves: a quantitative videodensitometric assessment of aortic regurgitation, *EuroIntervention.* 14 (2018) e416–e417, <https://doi.org/10.4244/EIJ-D-18-00196>.
  - [24] H. Tateishi, C.M. Campos, M. Abdelghani, R.S. Leite, J.A. Mangione, L. Bary, O. I. Soliman, E. Spitzer, M.A. Perin, Y. Onuma, et al., Video densitometric assessment of aortic regurgitation after transcatheter aortic valve implantation: results from the Brazilian TAVI registry, *EuroIntervention.* 11 (2016) 1409–1418, <https://doi.org/10.4244/EIJV11I12A271>.
  - [25] M. Barbanti, T.H. Yang, J. Rodes Cabau, C. Tamburino, D.A. Wood, H. Jilalawi, P. Blanke, R.R. Makkar, A. Latib, A. Colombo, et al., Anatomical and procedural features associated with aortic root rupture during balloon-expandable transcatheter aortic valve replacement, *Circulation.* 128 (2013) 244–253, <https://doi.org/10.1161/CIRCULATIONAHA.113.002947>.
  - [26] R.D. Sellers, M.J. Levy, K. Amplatz, C.W. Lillehei, Left retrograde cardioangiography in acquired cardiac disease: technic, indications and interpretations in 700 cases, *Am. J. Cardiol.* 14 (1964) 437–447, [https://doi.org/10.1016/0002-9149\(64\)90027-x](https://doi.org/10.1016/0002-9149(64)90027-x).
  - [27] P. Blanke, P. Pibarot, R. Hahn, N. Weissman, S. Kodali, V. Thourani, R. Parvataneni, D. Dvir, C. Naoum, B.L. Norgaard, et al., Computed tomography-based oversizing degrees and incidence of paravalvular regurgitation of a new generation transcatheter heart valve, *JACC Cardiovasc Interv.* 10 (2017) 810–820, <https://doi.org/10.1016/j.jcin.2017.02.021>.
  - [28] H. Kawashima, R. Wang, D. Mylotte, D. Jagielak, F. De Marco, A. Ielasi, Y. Onuma, P. den Heijer, C.J. Terkelsen, W. Wijns, et al., Quantitative angiographic assessment of aortic regurgitation after transcatheter aortic valve implantation among three balloon-expandable valves, *Glob. Heart* 16 (2021) 20, <https://doi.org/10.5334/gh.959>.
  - [29] H. Kawashima, P.W. Serruys, D. Mylotte, L. Rosseel, I.J. Amat-Santos, R.S. Rao, Y. Onuma, W. Wijns, M. Abdel-Wahab, A. Baumbach, et al., Operator preference and determinants of size selection when additional intermediate-size aortic transcatheter heart valves are made available, *Int. J. Cardiol.* 338 (2021) 168–173, <https://doi.org/10.1016/j.ijcard.2021.06.029>.
  - [30] A.B. Willson, J.G. Webb, T.M. Labounty, S. Achenbach, R. Moss, M. Wheeler, C. Thompson, J.K. Min, R. Gurvitch, B.L. Norgaard, et al., 3-dimensional aortic annular assessment by multidetector computed tomography predicts moderate or severe paravalvular regurgitation after transcatheter aortic valve replacement: a multicenter retrospective analysis, *J. Am. Coll. Cardiol.* 59 (2012) 1287–1294, <https://doi.org/10.1016/j.jacc.2011.12.015>.
  - [31] H. Kawashima, O. Soliman, R. Wang, M. Ono, H. Hara, C. Gao, E. Zeller, A. Thakkar, C. Tamburino, F. Bedogni, et al., Rationale and design of a randomized clinical trial comparing safety and efficacy of myval transcatheter heart valve versus contemporary transcatheter heart valves in patients with severe symptomatic aortic valve stenosis: the LANDMARK trial, *Am. Heart J.* 232 (2021) 23–38, <https://doi.org/10.1016/j.ahj.2020.11.001>.